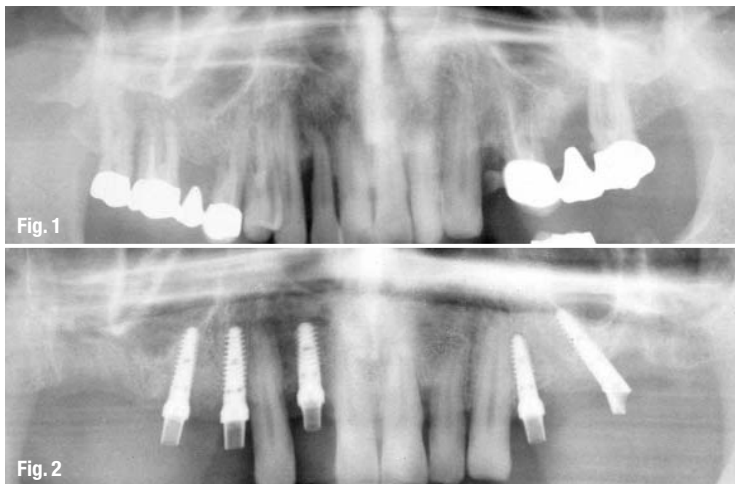


# Use of tilted implants in the treatment of the edentulous maxillary...

Author\_Prof Gregor-Georg Zafiropoulos, Germany



**Fig. 1** The orthopantomogram shows the initial situation.

**Fig. 2** Individual implant abutments 14 and 16 (both inserted axially).

**Fig. 3** Individual implant abutments 24 (inserted axially) and 26 (tilted).

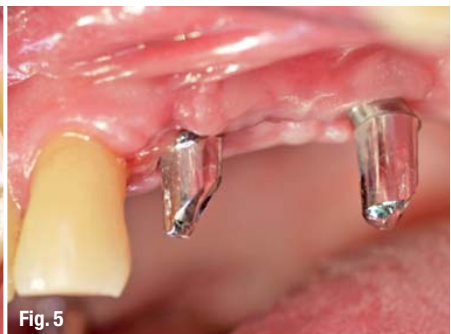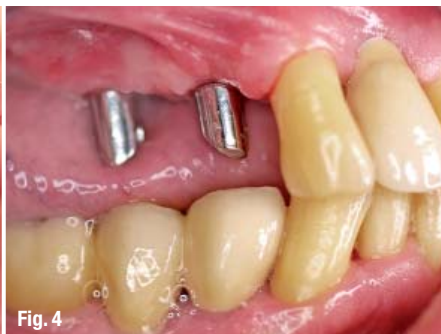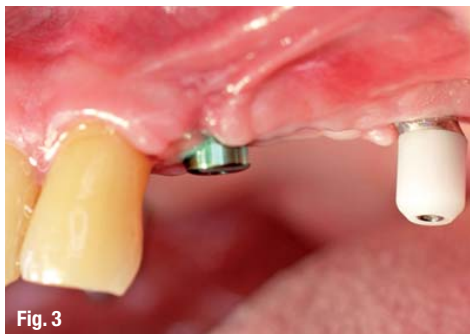**Fig. 4** The orthopantomogram shows implant placement and impression.

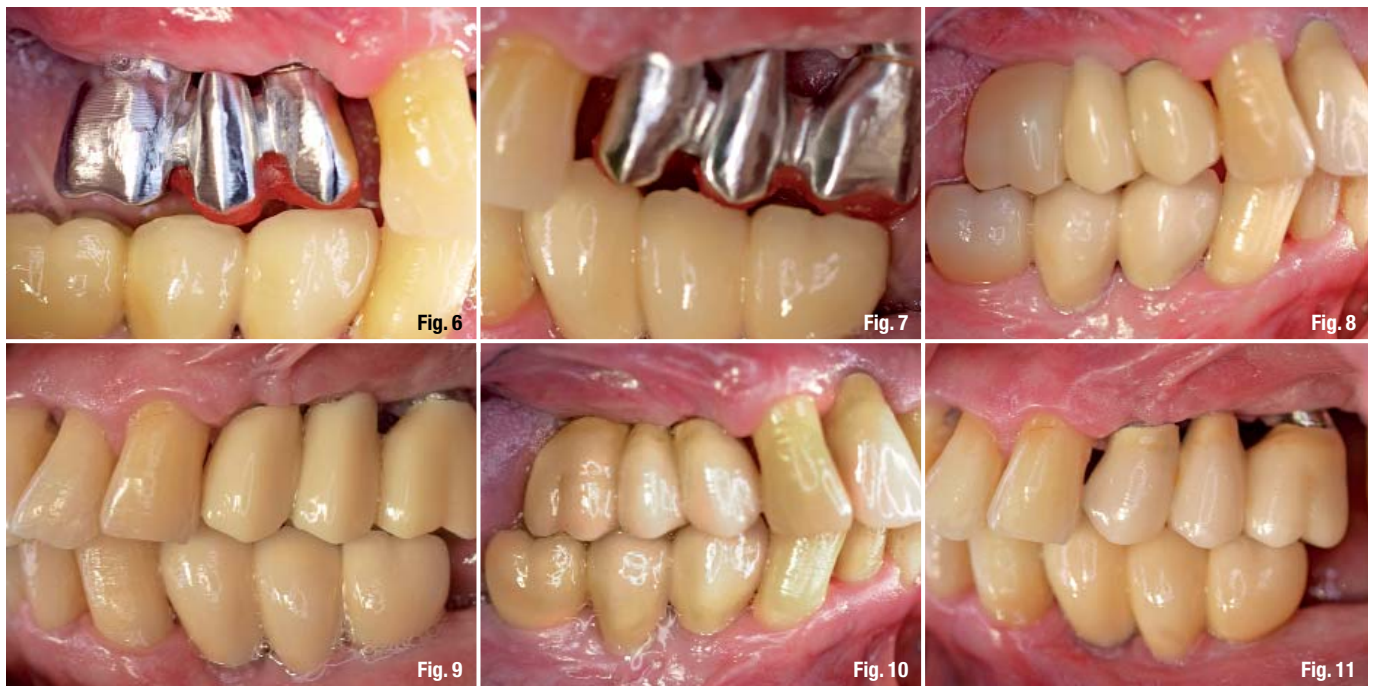
This case report describes the technique of implant insertion in the edentulous maxillary posterior region at an angle of 35° to avoid a sinus lift procedure and immediate restoration using fixed partial dentures (FPD), e.g. bridges.

Since the introduction of the technique of inserting posterior tilted implants at an angle of up to 35° (in relation to the vertical axis) and the corresponding prefabricated abutments for the treat-

ment of the edentulous maxilla or mandible, implant dentistry has experienced a change in its previously established, conventional surgical and prosthetic thinking (Maló *et al.* 2003, 2005, 2006). With implants inserted in this unorthodox manner, implementation of regenerative measures in the posterior regions of the atrophic and/or partially edentulous maxilla and mandible is avoided, allowing immediate loading and restoration. Clinical studies show that the success and survival rate of implants inserted at such an angle are comparable to those inserted at a conventional angle (Khatami & Smith 2008; Krekmanov *et al.* 2000; Hinze *et al.* 2010). Further results demonstrated that there was no significant difference in bone loss between implants inserted with a conventional axis and those inserted at an angle (regardless of jaw and/or region; Zampelis *et al.* 2007; Francetti *et al.* 2010).

This implantation technique was developed for the rehabilitation of an edentulous jaw, but only very little information is available about its application for rehabilitation of partial edentulism in posterior regions with FPD (Roccuzzo *et al.* 2009; Cordaro *et al.* 2009). This report presents observations made over one year of a representative case, in which the edentulous posterior regions of the max-





illa were reconstructed using implant-supported FPDs.

### Case report

A 51-year-old male patient (non-smoker) presented himself at the practice of a colleague because of advanced periodontal destruction in the maxillary arch one year before the start of the treatment described in this report (Fig. 1). Teeth #12, 14 to 18, 24 (retained root) and 25 to 27 were extracted. The extraction sockets were covered with dPTFE membranes (Cytoplast, Osteogenics Biomedical) with no additional use of grafting material, as previously described (Hoffmann *et al.* 2008; Zafiroopoulos *et al.* 2010). The mucoperiosteal flap was repositioned and fixed in the region of the papillae using interrupted sutures (Cytoplast, Osteogenics Biomedical). The membranes remained partially exposed and were removed after four weeks. The edentulous areas were then fitted with a model cast prosthesis.

About one year after the extractions in the maxilla, the patient presented at our practice for implant treatment. The patient suffered from bilateral chronic sinusitis and would not allow a sinus augmentation to be performed. Five implants (3.75 mm in diameter and 11.5 mm in length; SoftBone, Dentegris) were placed in regions 12, 14, 16, 24 and 26. The implants inserted in regions 12, 14, 16 and 24 were inserted conventionally, i.e. axially, and an internal sinus lift was performed in region 16 (Fig. 2). The implant inserted in region 26 was inserted at an angle of 35° to the vertical axis and immediately provided with a 35° titanium abutment (DAAS abut-

ment 35°, Dentegris; Fig. 3). An impression was taken using system-specific impression posts (pickup posts were used for the axially placed implants and DAAS posts for the tilted implants, both Dentegris) and a polyether impression material (Impregum, 3M ESPE; Fig. 4). The implants were then provided with system-specific healing caps (Dentegris; Fig. 5).

Three days after implantation, transfer keys were used to fit individual abutments. To fabricate the individual abutments, platinum/iridium/plastic abutments (PTIR abutments, Dentegris) were used as a modelling aid consisting of a prefabricated cast-on base made of platinum-iridium and a screw channel made of residue-free burn-out plastic. To fabricate the abutment for 26, a system-specific castable plastic cylinder (DAAS plastic cylinder, Dentegris) was used. On the same day, both a metal framework made of a cobalt-chromium alloy (ZENOTEC NP, Wieland) and a temporary restoration made of plastic (ZENO-PMMA; Wieland) were milled for immediate restoration of implants 14 to 16 and 24 to 26. The

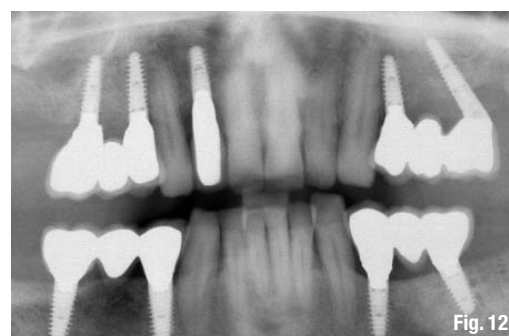**Fig. 5** Implants with healing caps (here an axially placed implant in region 24 and an implant placed at a 35° angle with a DAAS healing cap in region 26).

**Figs. 6 & 7** Fitting of the metal frameworks.

**Figs. 8 & 9** The implants loaded with temporary FPDs made of ZENO-PMMA.

**Figs. 10 & 11** The implants loaded with final metal ceramic FPDs.

**Fig. 12** Orthopantomogram after restoration.



framework was fitted and the temporary restoration was fixed using a temporary cement (Temp-Bond, Kerr; Figs. 6–11). Four months after implant placement and progressive immediate loading with the long-term temporary restoration, the final restoration was fitted using a temporary eugenol-free cement (Implant-Provisional, Alvelogro; Fig. 12).

## **Conclusion**

Under certain conditions (no active periodontal disease, good patient cooperation, good bone quality), successful early or immediate loading of implants in the posterior maxilla is possible in selected cases. Primary stability and implant design play a major role in the success of the implantation and restoration/loading of bridge restorations on tilted implants (Javed & Romanos 2010, Javed *et al.* 2011). On the basis of the scientific results published to date, it is not possible to discuss evidence-based contra-indications (based on the required and measurable values of primary stability, bone density and quality, and influence of occlusal forces). As a result, many questions remain unanswered and risks uncertain (Rocuzzo *et al.* 2009).

In our opinion, the primary benefit of using tilted implants is not necessarily the option of immediate implantation and loading, but firstly the avoidance of augmentative measures (e.g. sinus lift) and secondly treatment with a fixed restoration (Rosén & Gynther 2007; Aparicio *et al.* 2001). Regardless of the many positive scientific reports, the dentist should be aware of the risk of implant loss associated with immediate implant placement and loading. In addition, the dentist should define his/her own limits and select patients based on strict criteria.

*Editorial note: A list of references is available from the publisher.*

**\_contact**

**implants**

**Prof G.-G. Zafiropoulos**

Blaues Haus, Sternstr. 61  
40479 Düsseldorf  
Germany

[zafiropoulos@blaues-haus-duesseldorf.de](mailto:zafiropoulos@blaues-haus-duesseldorf.de)